



ACOG COMMITTEE OPINION

Number 789

Committee on Adolescent Health Care

This Committee Opinion was developed by the American College of Obstetricians and Gynecologists' Committee on Adolescent Health Care in collaboration with committee members Jennie Yoost, MD and Ashlyn Savage, MD.

Screening and Management of the Hyperandrogenic Adolescent

ABSTRACT: Although androgen excess can manifest in many ways, the most common and recognizable symptoms are hirsutism and acne. Reports of hirsutism and acne should be taken seriously because of their possible association with medical disorders, their substantial effect on self-esteem and quality of life, and the potential for psychosocial morbidity. In patients with symptoms of androgen excess, the differential diagnosis should include physiologic hyperandrogenism of puberty, idiopathic hyperandrogenism, and polycystic ovary syndrome (PCOS). There is a great deal of overlap between the symptoms of PCOS and those of normal puberty, which makes the diagnosis of PCOS in the adolescent difficult. Treatment of acne and hirsutism should not be withheld during the ongoing longitudinal evaluation for possible PCOS. On physical examination, body mass index, blood pressure, and signs of hyperandrogenism, such as acne and hirsutism, should be evaluated. Although guidelines differ on recommended laboratory studies, most include measurement of total testosterone, free testosterone, or both, and screening for nonclassic congenital adrenal hyperplasia with a 17-hydroxyprogesterone test. Elevation of the free or total testosterone level higher than the adult female normative values is a key diagnostic feature of biochemical hyperandrogenism. Because treatment is indicated only when symptoms are distressing to the patient, the degree to which acne or hirsutism bothers the patient should be assessed. Before initiation of any medical therapy, expectations of treatment should be discussed with the patient. Anticipatory guidance is critical to help patients understand the timeline for expected responses to therapy.

Recommendations and Conclusions

The American College of Obstetricians and Gynecologists makes the following recommendations and conclusions:

- Reports of hirsutism and acne should be taken seriously because of their possible association with medical disorders, their substantial effect on self-esteem and quality of life, and the potential for psychosocial morbidity.
- The diagnosis of hyperandrogenism can be based on clinical symptoms or measurement of serum androgens.
- There are no clear consensus guidelines on the diagnostic criteria for polycystic ovary syndrome (PCOS) in adolescent girls within 2 years of menarche; thus, obstetrician–gynecologists should exercise caution in assigning this diagnosis prematurely.
- Treatment of acne and hirsutism should not be withheld during the ongoing longitudinal evaluation for possible PCOS.
- Pelvic ultrasonography is not routinely indicated unless serum androgen levels or the degree of virilization is concerning for an ovarian tumor.
- The finding of polycystic ovarian morphology on ultrasonography has a prevalence in adolescent girls of 30–40% and alone is not predictive of the presence or future development of PCOS.
- Multimodal therapy is the most effective approach to the treatment of hirsutism; this includes lifestyle changes, physical hair removal, and androgen suppression or blockade with medication that slows or prevents new hair growth.

- Hormonal therapy should not be started before menarche. Once initiated, patients should be counseled that it may take 6 months before they see the benefits of treatment.
- Any estrogen-containing therapy should be effective at reducing acne, and oral contraceptive pills (OCPs) particularly are effective for adolescents who report premenstrual acne flare-ups.
- Patients should be assessed at routine intervals (every 3–6 months) for adverse effects and response to treatment until their condition is stable; they then should be monitored annually.
- Monitoring serum androgens is not recommended.

Introduction

Although androgen excess can manifest in many ways, the most common and recognizable symptoms are hirsutism and acne. (Alopecia also may be a symptom.) Hirsutism affects 5–10% of reproductive-aged females and is defined as excessive terminal hair growth in a distribution typically seen in adult men (face, sternum, lower abdomen, back, and thighs) (1). Acne vulgaris is a multifactorial skin condition of varying severity that affects as many as 90% of all adolescents (2). It is critical that the commonality of these conditions does not lead obstetrician–gynecologists and other health care providers to dismiss them as trivial. Reports of hirsutism and acne should be taken seriously because of their possible association with medical disorders, their substantial effect on self-esteem and quality of life, and the potential for psychosocial morbidity (3). In patients with symptoms of androgen excess, the differential diagnosis should include physiologic hyperandrogenism of puberty, idiopathic hyperandrogenism, and PCOS. Other less common potential causes of hyperandrogenism include nonclassic congenital adrenal hyperplasia, androgen-secreting tumors, hypothyroidism, Cushing disease, and severe hyperprolactinemia.

The diagnosis of hyperandrogenism can be based on clinical symptoms or measurement of serum androgens. In females, androgens originate from three primary sources: (1) the ovarian theca, (2) the adrenal cortex, and (3) within end organs by peripheral conversion. The major androgens include dehydroepiandrosterone, dehydroepiandrosterone sulfate (DHEAS), androstenedione, testosterone, and dihydrotestosterone, with the latter two having the highest affinity for the androgen receptor and the greatest potency. In healthy women, testosterone is largely bound by sex hormone binding globulin and albumin, leaving only approximately 1% freely circulating as bioactive “free testosterone” (4). The pilosebaceous unit expresses 5 α -reductase, which converts testosterone to the highly potent dihydrotestosterone. Varying expression of enzyme activity within the pilosebaceous unit leads to a lack of clear correlation between serum androgens and the presence or severity of acne and hirsutism. There also may be ethnic and familial variability (5).

Polycystic ovary syndrome is the most common cause of persistent hyperandrogenism beyond early puberty in adolescent girls and women and is estimated to affect 6–15% of reproductive-aged women (6). In this syndrome, chronically elevated luteinizing hormone and insulin levels lead to increased androgen production within the ovarian theca. In addition, hyperinsulinemia suppresses hepatic production of sex hormone binding globulin, which results in increased levels of free testosterone (4). There is a great deal of overlap between the symptoms of PCOS and those of normal puberty (eg, irregular menses, acne, polycystic ovarian morphology on ultrasonography), which makes the diagnosis of PCOS in the adolescent difficult.

There are no clear consensus guidelines on the diagnostic criteria for PCOS in adolescent girls within 2 years of menarche; thus, obstetrician–gynecologists should exercise caution in assigning this diagnosis prematurely. Most experts agree that longitudinal evaluation of symptoms such as acne, hirsutism, and oligomenorrhea should occur over the span of the first 1–2 years after menarche before establishing a diagnosis of PCOS. Obstetrician–gynecologists also should recognize that PCOS exists along a spectrum that may evolve over time and can present differently among different ethnicities. Treatment of acne and hirsutism should not be withheld during the ongoing longitudinal evaluation for possible PCOS. In addition, although obesity and insulin resistance are not diagnostic criteria for PCOS, they often co-exist in this population and warrant early counseling on healthy weight, nutrition, and exercise and evaluations to exclude diabetes (7).

Evaluation of the Hyperandrogenic Adolescent

The initial evaluation should focus on identifying clinical signs or symptoms of androgen excess and determining if further evaluation is indicated (Fig. 1). The medical history should include the following: age of thelarche, adrenarche, and menarche; past laser hair removal; shaving; off-label use of anabolic steroids or testosterone; and menstrual history, including frequency and duration. Other important aspects of the history may include premature adrenarche and low birth weight. The timing and progression of acne and hirsutism, along with a record of previous therapies, are helpful for management. A history of rapid onset of virilization (deepening of the voice or frontal balding) is more concerning for androgen secreting tumors. If obesity is present, timing and progression of weight gain should be assessed. A family history of hirsutism, severe acne, PCOS, or obesity also should be recorded. Importantly, some adolescents are not bothered by their symptoms of hyperandrogenism. Because treatment is indicated only when symptoms are distressing to the patient, the degree to which acne or hirsutism bothers the patient should be assessed. For acne, obstetrician–gynecologists should consider counseling about the potential for long-term scarring of the skin if left untreated.

On physical examination, body mass index, blood pressure, and signs of hyperandrogenism, such as acne

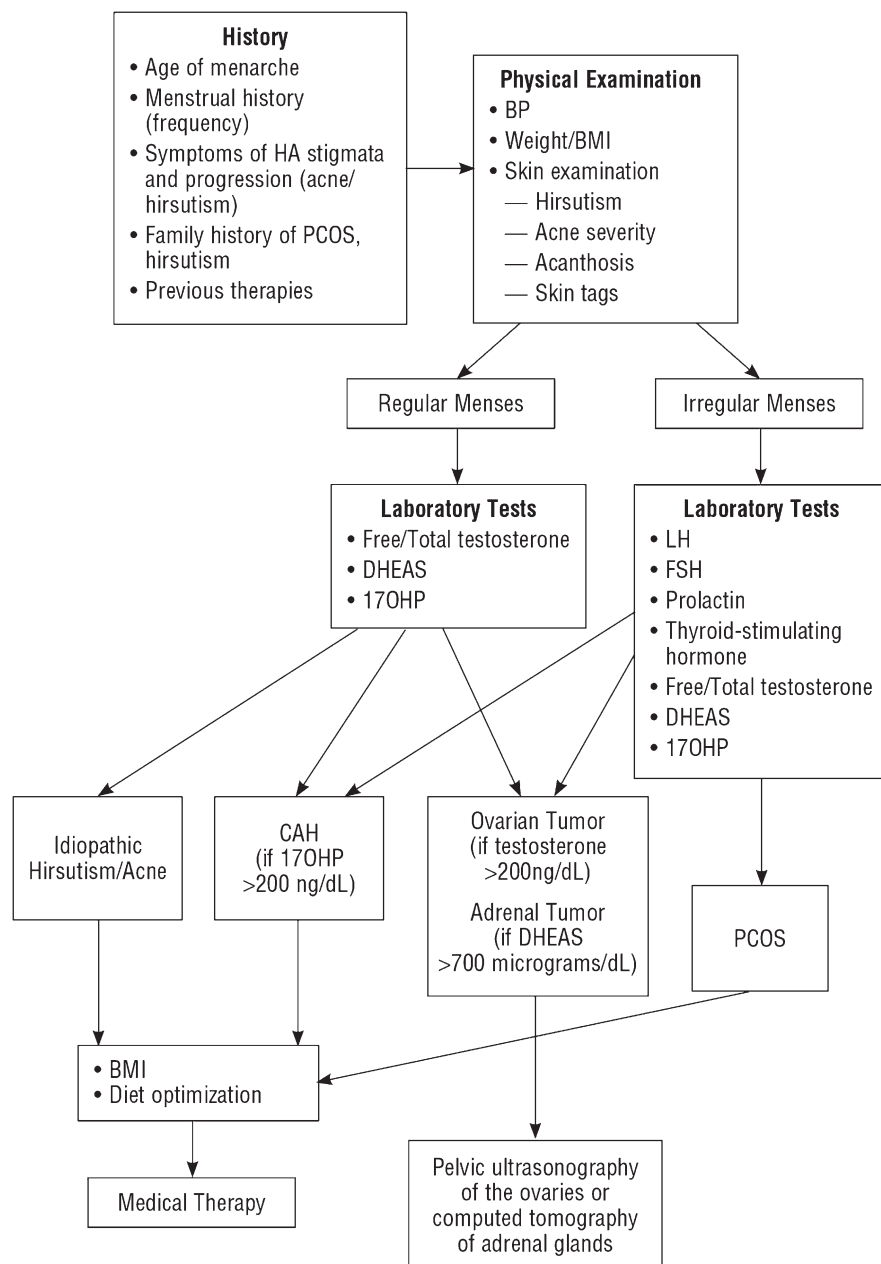


Figure 1. Evaluation and Management of Clinical Hyperandrogenism. Abbreviations: BMI, body mass index; BP, blood pressure; CAH, congenital adrenal hyperplasia; DHEAS, dehydroepiandrosterone sulphate; FSH, follicle-stimulating hormone; HA, hyperandrogenism; LH, luteinizing hormone; 17OHP, 17- α -hydroxyprogesterone; PCOS, polycystic ovary syndrome.

and hirsutism, should be evaluated. It also is useful to assess for signs of insulin resistance, such as hypertension, obesity, centripetal fat distribution, skin tags, and acanthosis nigricans. Examination of androgen-sensitive skin areas such as the face, chest, abdomen, and back provide an assessment of the degree of hirsutism and can be used to chart patient progress over time; Ferriman–Gallwey scoring can be done if

desired. Modified Ferriman–Gallwey (Fig. 2) scoring evaluates nine areas of the body; a score greater than 8 is indicative of hirsutism (3). Grading systems for acne include quantity (mild, moderate, or severe), location, and quality (comedonal, inflammatory [including erythematous papules and pustules or nodules], or mixed). There is no universally agreed upon grading scale (8).

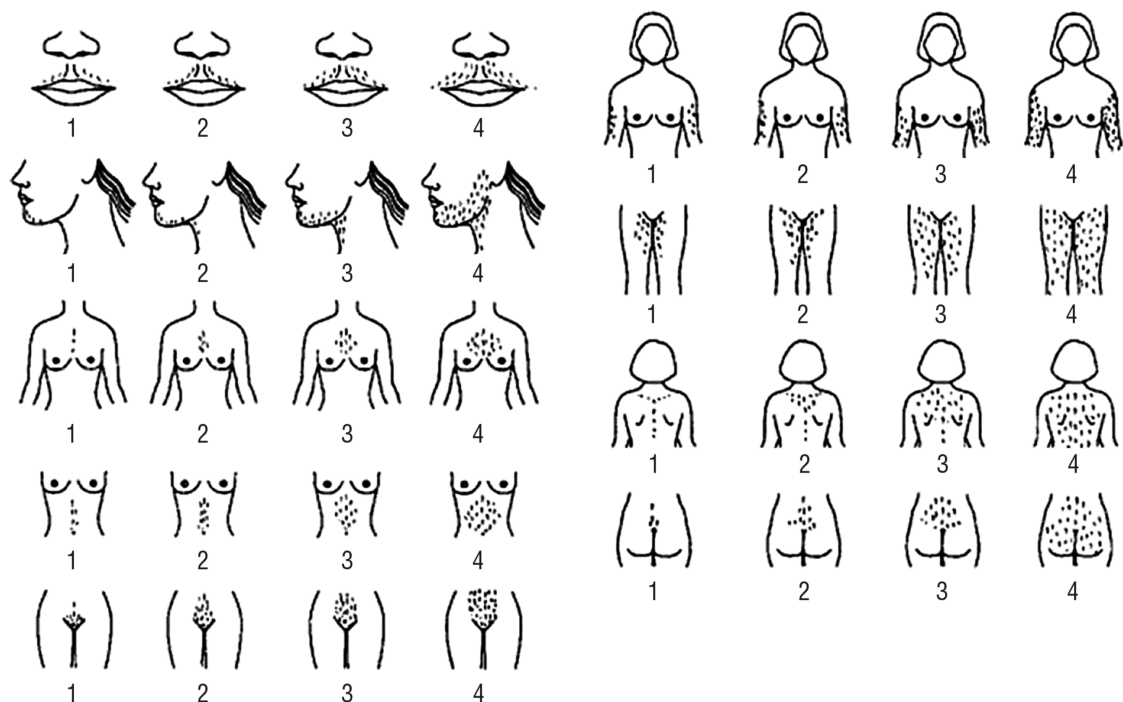


Figure 2. Modified Ferriman–Gallwey Scoring System. Nine body areas (upper lip, chin, chest, arm, upper abdomen, lower abdomen, upper back, lower back and thighs) are scored from 1 (minimal terminal hairs present) to 4 (equivalent to a hairy man). If no terminal hairs are observed in the body area being examined the score is 0 (left blank). Clinically terminal hairs can be distinguished from vellus hairs primarily by their length (eg, greater than 0.5 cm) and the fact that they are usually pigmented. (Reprinted from Yildiz BO, Bolour S, Woods K, Moore A, Azziz R. Visually scoring hirsutism. *Hum Reprod Update* 2010;16:51–64.)

External examination of the genitalia may be helpful to rule out clitoromegaly, but an internal vaginal examination is rarely indicated. Although there is variability, for adolescents aged 13–16 years, clitoromegaly is diagnosed when the crosswise width of the glans is greater than 8 mm and the length of the hood is greater than 27.4 mm (9). Larger widths may be concerning for virilization and should prompt laboratory androgen assessment. Pelvic ultrasonography is not routinely indicated unless serum androgen levels or the degree of virilization is concerning for an ovarian tumor (Fig. 1). The finding of polycystic ovarian morphology on ultrasonography has a prevalence in adolescent girls of 30–40% and alone is not predictive of the presence or future development of PCOS (10). If ultrasonography is performed, patients should be reassured that a multifollicular pattern is not tumor related and does not confirm a diagnosis of PCOS.

Although guidelines differ on recommended laboratory studies, most include measurement of total testosterone, free testosterone, or both, and screening for nonclassic congenital adrenal hyperplasia with a 17-hydroxyprogesterone test (11, 12). Total testosterone can be affected by diurnal rhythms, phase of menstrual cycle, and sex hormone binding globulin concentrations. Laboratory use of high-quality radioimmunoassays are recommended rather than enzyme-linked immunosorbent or chemiluminescent assays, which have poorer sensitiv-

ity (13). Elevation of the free or total testosterone level higher than the adult female normative values is a key diagnostic feature of biochemical hyperandrogenism. Total testosterone levels greater than 200 ng/dL are suggestive of a virilizing tumor and should prompt pelvic ultrasonography (12). Ideally, blood should be drawn for the serum 17-hydroxyprogesterone test first thing in the morning (14); a level greater than 200 ng/dL is suggestive of nonclassic congenital adrenal hyperplasia. Supplemental testing includes a corticotropin (formerly adrenocorticotrophic hormone [ACTH]) stimulation test for confirmation of nonclassic congenital adrenal hyperplasia and DHEAS to rule out adrenal neoplasm; this may be appropriate in cases of rapid onset of virilization (15). Computed tomography scans to evaluate the adrenal glands should be obtained for patients with markedly elevated DHEAS levels. Alternatively, adrenal ultrasonography can be offered if adrenal glands can be visualized. See Figure 1 for suggested laboratory tests. Like adult patients, adolescents with suspected PCOS should be screened for diabetes and hyperlipidemia (7).

Management

Hirsutism

Multimodal therapy is the most effective approach to the treatment of hirsutism; this includes lifestyle changes,

physical hair removal, and androgen suppression or blockade with medication that slows or prevents new hair growth. Patients also should be counseled that given the life span of terminal hair, 6 months of medical therapy is required before slower and finer regrowth of hair is noted (15).

All patients who present with clinical hyperandrogenism should be counseled on a healthy lifestyle. Weight loss in obese patients with hyperandrogenemia with or without PCOS has been shown to decrease androgen levels, increase sex hormone binding globulin, and reduce clinical hirsutism (16). In turn, weight management and glycemic control can be helpful interventions to address symptoms of androgen excess.

No combined hormonal contraceptive has been approved by the U.S. Food and Drug Administration for the treatment of hirsutism. Combined hormonal contraceptives, which suppress luteinizing hormone-mediated ovarian androgen synthesis, can be used as monotherapy.

Ethinyl estradiol leads to an increase in sex hormone binding globulin, which reduces free (biologically active) testosterone. Although most data about the treatment of hyperandrogenism are on OCPs, similar effects have been shown with the patch and vaginal ring formulations (17, 18). Among the formulations, OCPs that contain third-generation progestins, such as desogestrel, gestodene, and norgestimate, have less androgenic activity when compared with second-generation progestins (levonorgestrel). Drospirenone, a progestin derived from spironolactone, has anti-mineral corticosteroids and antiandrogenic properties and is frequently used to treat hirsutism. The amount of drospirenone contained in OCPs is equivalent to 25 mg of spironolactone (15). Also, although these methods work to slow growth, they do not remove existing hair.

Hormonal therapy should not be started before menarche. Once initiated, patients should be counseled that it may take 6 months before they see the benefits of treatment. If response is suboptimal after 6 months,

Table 1. Management of Acne in Adolescents and Young Adults*

	Mild	Moderate [†]	Severe [†]
1st Line Treatment*	BP or topical retinoid or Topical combination therapy [‡] • BP + antibiotic or • Retinoid + BP or • Retinoid + BP + antibiotic	Topical combination therapy [‡] • BP + antibiotic or • Retinoid + BP or • Retinoid + BP + antibiotic or Oral antibiotic + topical retinoid + BP or Oral antibiotic + topical retinoid + BP + topical antibiotic	Oral antibiotic + topical combination therapy [‡] • BP + antibiotic or • Retinoid + BP or • Retinoid + BP + antibiotic or Oral isotretinoin [§]
Alternative Treatment	Add topical retinoid or BP (if not on already) or Consider alternate retinoid or Consider topical dapsone	Consider alternate combine therapy or Consider change in oral antibiotic or Add combined oral contraceptive or oral spironolactone (females) or Consider oral isotretinoin [§]	Consider change in oral antibiotic or Add combined oral contraceptive or oral spironolactone (females) or Consider oral isotretinoin [§]

Abbreviation: BP, benzoyl peroxide.

*Hormonal therapy, such as a combination oral contraceptive pill, also can be considered an acceptable first-line treatment for patients desiring this method.

[†]Working with a dermatologist can be beneficial for patients with moderate to severe acne or acne refractory to initial medical therapy. Referral to dermatologist should be made for complex cases.

[‡]The drug may be prescribed as a fixed combination product or as separate component.

[§]Patients with severe acne requiring oral isotretinoin are required by the U.S. Food and Drug Administration to register and comply with the iPLEDGE program, its risk evaluation, and mitigation strategy. (Information about the iPLEDGE program is available at <https://www.ipleadgeprogram.com/iPledgeUI/home.u>). These patients should be counseled to use dual methods of contraception because of the significant risk of teratogenicity.

Adapted from Zaengle AL, Pathy AL, Schlosser BJ, Alikhan A, Baldwin HE, Berson DS, et al. Guidelines of care for the management of acne vulgaris. *J Am Acad Dermatol* 2016;74:73.945–73.e33.

additional hair removal therapies or antiandrogens can be added. For moderate-to-severe hirsutism, hormonal therapy and antiandrogens can be started concomitantly.

Antiandrogens prevent testosterone and other androgens from expressing their activity at the level of the pilosebaceous unit and can be used to enhance the effect of combined hormonal therapy (15). Spironolactone is approved for the treatment of hirsutism and works as a competitive inhibitor of the androgen receptor and 5 α -reductase inhibitor. It also is an aldosterone antagonist. Typical doses for the treatment of hirsutism range from 50 to 200 mg daily (19). Spironolactone has been associated with menstrual irregularity. Spironolactone may affect the genital development of a male fetus; therefore, it should be used with contraception in patients who engage in sexual activity that could result in pregnancy. Adverse effects for the adolescent include diuresis, hypotension, and risk of hyperkalemia, which is rare in patients with normal renal function.

Other antiandrogens, such as flutamide, have demonstrated a similar efficacy to spironolactone, but are used less commonly because of the potential for hepatotoxicity (3). There are limited data on the efficacy of finasteride in adolescents (20). See ACOG Practice Bulletin No. 194, *Polycystic Ovary Syndrome*, for more information. Metformin is an insulin sensitizer that may reduce serum androgens and can be used in the setting of insulin resistance in adolescents with PCOS (11, 21). Among adolescents randomized to metformin or spironolactone, both medications improved hirsutism, but spironolactone showed a greater benefit (22). A recent meta-analysis of four trials specific to adolescent females showed that OCPs and metformin were similar in terms of effect on hirsutism (23). Further studies are needed to elucidate long-term benefits of insulin-sensitizing agents for adolescent girls and women (7).

Physical methods of hair removal such as bleaching, shaving, waxing, chemical depilatories, electrolysis, and laser therapy can be used safely and effectively. Of these, only electrolysis and laser therapy permanently affect the underlying hair follicle (3). Laser therapy operates by selective thermolysis whereby the melanin pigment in the follicle absorbs the selected wavelength, which results in follicle destruction. A clinical reduction in hair can be achieved with laser therapy in patients who have lighter skin and darker hair (24). In patients with darker skin types, hair reduction also is achievable with laser therapy using longer wavelengths and appropriate energy settings (25).

Eflornithine cream is approved for the treatment of facial hirsutism and is a topical inhibitor of L-ornithine decarboxylase, the enzyme critical to cell growth and differentiation within the hair follicle. Continuous topical administration slows facial hair growth, but is limited to small areas of use, and hair growth recurs when discontinued (26).

Acne

A variety of therapies can be used to treat acne in adolescents (Table 1). As with hirsutism, multimodal

therapy may be more effective, and response to therapy may take several months. Working with a dermatologist can be beneficial for patients with moderate-to-severe acne or acne refractory to initial medical therapy. Referral to a dermatologist should be made for complex cases. Acne treatment algorithms often show topical therapy as a first-line approach. Many patients will have tried multiple over-the-counter topical regimens before coming to their obstetrician–gynecologists. However, even in patients who have not used other medications, hormonal therapy, such as a combination OCP, can be considered an acceptable first-line treatment for patients who desire this method.

Topical therapy includes medications that are available over-the-counter or by prescription. The type of topical therapy can be influenced by affected site, severity of disease, or patient preference. Topical agents can be used alone, with other topical therapies, or in combination with oral agents (8). Benzoyl peroxide can be found in over-the-counter products, and patients should be counseled that it can bleach hair or clothing. Patients also may have concerns about skin sensitivities to various topical agents, and often a dose escalation regimen can be used for tolerability (eg, applying the medication every other night for 1–2 weeks before advancing to every night). The type of agent and patient skin type also should be considered; for example, patients with oily skin may prefer gels or solutions, whereas those with drier skin may prefer creams (27).

Hormonal therapy is an acceptable first-line approach to management of acne for postmenarchal adolescents. This approach may be particularly appealing to adolescents who are also interested in menstrual cycle control, contraception, or both. Any estrogen-containing therapy should be effective at reducing acne, and OCPs particularly are effective for adolescents who report premenstrual acne flare-ups (28). Although progestins vary in their androgenic potential, when combined with the effects of ethinyl estradiol, the net effect of all OCPs is antiandrogenic (8). However, for patients who do not show improvement on first or second generation progestins, a third or fourth generation progestin may be helpful.

Spironolactone can be used for the treatment of acne; the response is dose dependent. Dosages of 25 mg daily have been shown to be effective in some patients and can be increased to a maximum dosage of 100–200 mg/d (19).

Oral antibiotics are typically used for moderate-to-severe acne, acne on the chest and back, and with inflammatory lesions where topical agents have not been useful. It is recommended that oral antibiotics be tapered or discontinued once new inflammatory lesions have stopped emerging, and other therapies may be used for maintenance (8, 27). Current antibiotics recommended for acne do not interact with hormonal contraception (29). Patients with severe acne that requires oral isotretinoin are required by the U.S. Food and Drug Administration to register and

comply with the iPLEDGE program and its risk evaluation and mitigation strategy. (Information about the iPLEDGE program is available at <https://www.ipledgeprogram.com/iPledgeUI/home.u>). These patients should be counseled to use dual methods of contraception (eg, condoms and an OCP) because of the significant risk of teratogenicity.

Follow-up

Before initiation of any medical therapy, expectations of treatment should be discussed with the patient. Managing the symptoms of hyperandrogenism may be a lifelong process. Patients should be assessed at routine intervals (every 3–6 months) for adverse effects and response to treatment until their condition is stable; they then should be monitored annually. With combination therapy, often antiandrogens can be discontinued or tapered over time, with continuation of oral contraception as monotherapy. Monitoring serum androgens is not recommended. Although data are unclear, consider monitoring potassium levels if patients taking spironolactone have medical comorbidities that affect renal function. Management should be individualized based on spironolactone dose and other comorbidities.

Conclusion

Symptoms of androgen excess are quite common among adolescents and can have a substantial effect on self-esteem and emotional well-being. Among adolescents presenting with these symptoms, it is a challenge to distinguish physiologic changes of puberty from PCOS. Often, a longitudinal assessment of a patient's symptoms, examination findings, and laboratory values are required before a health care provider can distinguish pubertal changes from PCOS. Adolescents with hirsutism or acne can be treated with a goal of symptom control before assignment of a final diagnosis. Anticipatory guidance is critical to help patients understand the timeline for expected responses to therapy.

References

1. Liu K, Motan T, Claman P. No. 350-hirsutism: evaluation and treatment. *J Obstet Gynaecol Can* 2017;39:1054–68.
2. Olutunmbi Y, Paley K, English JC 3rd. Adolescent female acne: etiology and management. *J Pediatr Adolesc Gynecol* 2008;21:171–6.
3. Escobar-Morreale HF, Carmina E, Dewailly D, Gambineri A, Kelestimur F, Moghetti P, et al. Epidemiology, diagnosis and management of hirsutism: a consensus statement by the Androgen Excess and Polycystic Ovary Syndrome Society [published erratum appears in *Hum Reprod Update* 2013;19:207]. *Hum Reprod Update* 2012;18:146–70.
4. Lizneva D, Gavrilova-Jordan L, Walker W, Azziz R. Androgen excess: Investigations and management. *Best Pract Res Clin Obstet Gynaecol* 2016;37:98–118.
5. Castelo-Branco C, Cancelo MJ. Comprehensive clinical management of hirsutism. *Gynecol Endocrinol* 2010;26:484–93.
6. Witchel SF, Roumimper H, Oberfield S. Polycystic ovary syndrome in adolescents. *Endocrinol Metab Clin North Am* 2016;45:329–44.
7. Polycystic ovary syndrome. ACOG Practice Bulletin No. 194. American College of Obstetricians and Gynecologists. *Obstet Gynecol* 2018;131:e157–71.
8. Zaenglein AL, Pathy AL, Schlosser BJ, Alikhan A, Baldwin HE, Berson DS, et al. Guidelines of care for the management of acne vulgaris. *J Am Acad Dermatol* 2016;74:73. 945–73.e33.
9. Iezzi ML, Lasorella S, Varriale G, Zagaroli L, Ambrosi M, Verrotti A. Clitoromegaly in childhood and adolescence: behind one clinical sign, a clinical sea. *Sex Dev* 2018;12:163–74.
10. Codner E, Villarroel C, Eyzaguirre FC, Lopez P, Merino PM, Perez-Bravo F, et al. Polycystic ovarian morphology in post-menarchal adolescents. *Fertil Steril* 2011;95:702–6.e1–2.
11. Huppert J, Chiodi M, Hillard PJ. Clinical and metabolic findings in adolescent females with hyperandrogenism. *J Pediatr Adolesc Gynecol* 2004;17:103–8.
12. Rosenfield RL. The diagnosis of polycystic ovary syndrome in adolescents. *Pediatrics* 2015;136:1154–65.
13. Azziz R, Carmina E, Dewailly D, Diamanti-Kandarakis E, Escobar-Morreale HF, Futterweit W, et al. The Androgen Excess and PCOS Society criteria for the polycystic ovary syndrome: the complete task force report. Task Force on the Phenotype of the Polycystic Ovary Syndrome of the Androgen Excess and PCOS Society. *Fertil Steril* 2009;91:456–88.
14. Speiser PW, Arlt W, Auchus RJ, Baskin LS, Conway GS, Merke DP, et al. Congenital adrenal hyperplasia due to steroid 21-hydroxylase deficiency: an Endocrine Society Clinical Practice Guideline [published erratum appears in *J Clin Endocrinol Metab* 2019;104:39–40]. *J Clin Endocrinol Metab* 2018;103:4043–88.
15. Martin KA, Anderson RR, Chang RJ, Ehrmann DA, Lobo RA, Murad MH, et al. Evaluation and treatment of hirsutism in premenopausal women: an Endocrine Society Clinical Practice Guideline. *J Clin Endocrinol Metab* 2018;103:1233–57.
16. Lim SS, Hutchison SK, Van Ryswyk E, Norman RJ, Teede HJ, Moran LJ. Lifestyle changes in women with polycystic ovary syndrome. The Cochrane Database of Systematic Reviews 2019, Issue 3. Art. No.: CD007506. DOI: 10.1002/14651858.CD007506.pub4.
17. White T, Jain JK, Stanczyk FZ. Effect of oral versus transdermal steroidal contraceptives on androgenic markers. *Am J Obstet Gynecol* 2005;192:2055–9.
18. Battaglia C, Mancini F, Fabbri R, Persico N, Busacchi P, Facchinetti F, et al. Polycystic ovary syndrome and cardiovascular risk in young patients treated with drospirenone-ethinylestradiol or contraceptive vaginal ring. A prospective, randomized, pilot study. *Fertil Steril* 2010;94:1417–25.
19. Rathnayake D, Sinclair R. Use of spironolactone in dermatology. *Skinmed* 2010;8:328–32; quiz 333.

20. Tartagni MV, Alrasheed H, Damiani GR, Montagnani M, De Salvia MA, De Pergola G, et al. Intermittent low-dose finasteride administration is effective for treatment of hirsutism in adolescent girls: a pilot study. *J Pediatr Adolesc Gynecol* 2014;27:161–5.
21. Obesity in adolescents. Committee Opinion No. 714. American College of Obstetricians and Gynecologists. *Obstet Gynecol* 2017;130:e127–40.
22. Ganie MA, Khurana ML, Eunice M, Gupta N, Gulati M, Dwivedi SN, et al. Comparison of efficacy of spironolactone with metformin in the management of polycystic ovary syndrome: an open-labeled study [published erratum appears in *J Clin Endocrinol Metab* 2004;89:4655]. *J Clin Endocrinol Metab* 2004;89:2756–62.
23. Al Khalifah RA, Florez ID, Dennis B, Thabane L, Bassilious E. Metformin or oral contraceptives for adolescents with polycystic ovarian syndrome: a meta-analysis. *Pediatrics* 2016;137:e20154089.
24. Sanchez LA, Perez M, Azziz R. Laser hair reduction in the hirsute patient: a critical assessment. *Hum Reprod Update* 2002;8:169–81.
25. Fayne RA, Perper M, Eber AE, Aldahan AS, Nouri K. Laser and light treatments for hair reduction in Fitzpatrick skin types IV–VI: a comprehensive review of the literature. *Am J Clin Dermatol* 2018;19:237–52.
26. Wolf JE Jr, Shander D, Huber F, Jackson J, Lin CS, Mathes BM, et al. Randomized, double-blind clinical evaluation of the efficacy and safety of topical eflornithine HCl 13.9% cream in the treatment of women with facial hair. Eflornithine HCl Study Group. *Int J Dermatol* 2007;46:94–8.
27. Eichenfield LF, Krakowski AC, Piggott C, Del Rosso J, Baldwin H, Friedlander SF, et al. Evidence-based recommendations for the diagnosis and treatment of pediatric acne. American Acne and Rosacea Society. *Pediatrics* 2013;131(suppl 3):163–86.
28. Katsambas AD, Dessinioti C. Hormonal therapy for acne: why not as first line therapy? Facts and controversies. *Clin Dermatol* 2010;28:17–23.
29. Simmons KB, Haddad LB, Nanda K, Curtis KM. Drug interactions between non-rifamycin antibiotics and hormonal contraception: a systematic review. *Am J Obstet Gynecol* 2018;218:88–97.e14.

Published online on September 24, 2019.

Copyright 2019 by the American College of Obstetricians and Gynecologists. All rights reserved. No part of this publication may be reproduced, stored in a retrieval system, posted on the Internet, or transmitted, in any form or by any means, electronic, mechanical, photocopying, recording, or otherwise, without prior written permission from the publisher.

Requests for authorization to make photocopies should be directed to Copyright Clearance Center, 222 Rosewood Drive, Danvers, MA 01923, (978) 750-8400.

American College of Obstetricians and Gynecologists
409 12th Street, SW, PO Box 96920, Washington, DC 20090-6920

Screening and management of the hyperandrogenic adolescent. ACOG Committee Opinion No. 789. American College of Obstetricians and Gynecologists. Obstet Gynecol 2019;134:e106–14.

This information is designed as an educational resource to aid clinicians in providing obstetric and gynecologic care, and use of this information is voluntary. This information should not be considered as inclusive of all proper treatments or methods of care or as a statement of the standard of care. It is not intended to substitute for the independent professional judgment of the treating clinician. Variations in practice may be warranted when, in the reasonable judgment of the treating clinician, such course of action is indicated by the condition of the patient, limitations of available resources, or advances in knowledge or technology. The American College of Obstetricians and Gynecologists reviews its publications regularly; however, its publications may not reflect the most recent evidence. Any updates to this document can be found on acog.org or by calling the ACOG Resource Center.

While ACOG makes every effort to present accurate and reliable information, this publication is provided “as is” without any warranty of accuracy, reliability, or otherwise, either express or implied. ACOG does not guarantee, warrant, or endorse the products or services of any firm, organization, or person. Neither ACOG nor its officers, directors, members, employees, or agents will be liable for any loss, damage, or claim with respect to any liabilities, including direct, special, indirect, or consequential damages, incurred in connection with this publication or reliance on the information presented.

All ACOG committee members and authors have submitted a conflict of interest disclosure statement related to this published product. Any potential conflicts have been considered and managed in accordance with ACOG’s Conflict of Interest Disclosure Policy. The ACOG policies can be found on acog.org. For products jointly developed with other organizations, conflict of interest disclosures by representatives of the other organizations are addressed by those organizations. The American College of Obstetricians and Gynecologists has neither solicited nor accepted any commercial involvement in the development of the content of this published product.